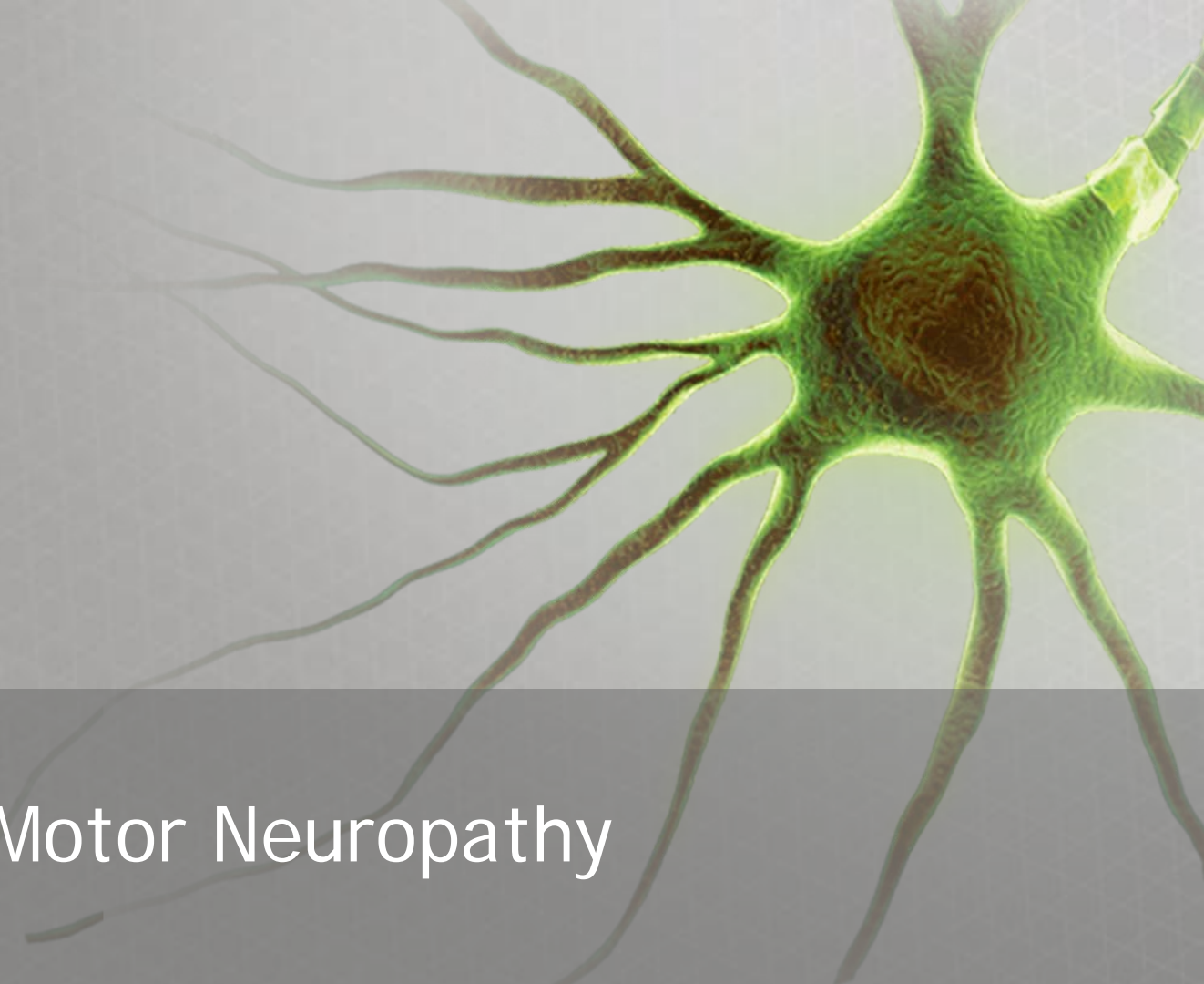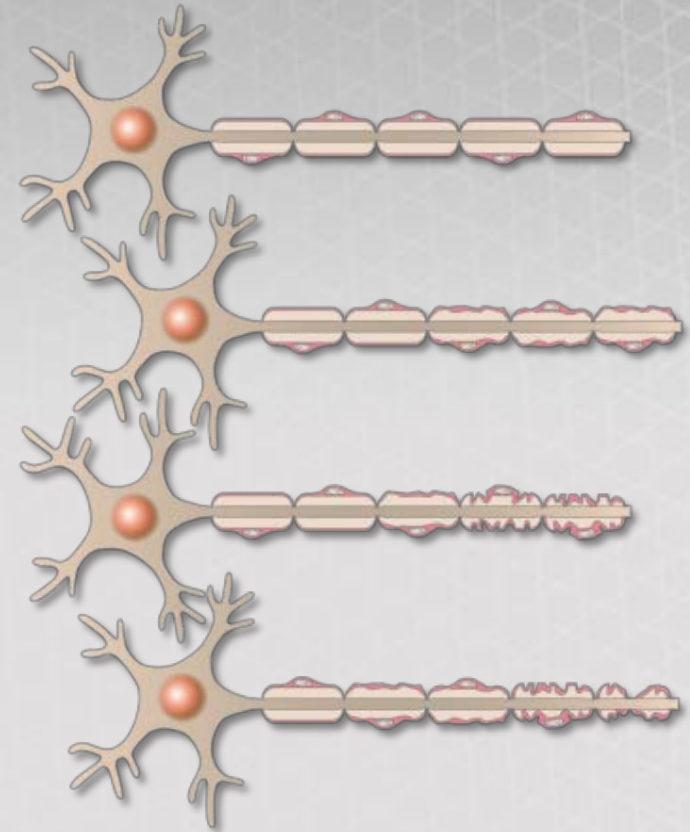


Multifocal Motor Neuropathy

Description of multifocal motor neuropathy (MMN)

- MMN is a rare, chronic, asymmetric motor neuropathy affecting predominantly distal extremities, arms and legs¹
 - MMN patients have focal block of motor nerve conduction
- The disease course is slowly progressive, extending over decades without spontaneous remission^{2,3}
- Usually presents before age 45; prevalence rates range from 1 to 2 cases per 100,000 with men being affected more often than women (2.6:1)³



Axon deterioration over time in MMN patients

1. Umapathi T *et al.* Cochrane Database Syst Rev. 2012;18(4):CD003217.
2. GBS/CIDP Foundation International. Available at: <http://www.gbs-cidp.org/variants/mmn-overview/>. Accessed Mar 2016.
3. Nobile-Orazio E *et al.* Muscle Nerve. 2005;31(6):663–680.

Signs and symptoms of MMN

- MMN presents as weakness without sensory loss, with asymmetric involvement of two or more nerves and absence of motor neuron signs¹
- Common signs and symptoms include:^{2,3}
 - General fatigue
 - Muscle cramping
 - Fasciculations
 - Conduction blocks
- Lack of sensory involvement with MMN is one of its distinguishing features^{2,3}
 - Although mild sensory symptoms are noted, significant sensory abnormalities in the region of motor weakness are not present

1. van Schaik IN *et al.* Chapter 21: Multifocal motor neuropathy. In: Gilhus, NE *et al.* (Ed). European Handbook of Neurological Management; Volume 1, 2nd Edition. 2011.
2. Hansen MD. Understanding and treating multifocal motor neuropathy. Available at: http://www.neuropathyaction.org/downloads/igl%20f-m11_mmn.pdf. Accessed Mar 2016.
3. Nobile-Orazio E *et al.* Muscle Nerve. 2005;31(6):663–680.

Prognosis for MMN patients¹

- If left untreated, MMN patients are likely to experience progressive muscle weakness that may result in serious functional impairment and impaired quality of life
- Delayed diagnosis may also have implications for response to IVIG
 - Early initiation of treatment may help to postpone axonal degeneration and permanent deficits

IVIG: intravenous immunoglobulin

Diagnostic guidelines for MMN¹

- The joint task force of the EFNS and PNS developed guidelines on MMN and updated them in 2011

Diagnosis (summary)

- Two core criteria and all exclusion criteria must be met
 - See next slide
- Definite or probable conduction block should be present in at least one nerve
- Supportive diagnosis:
 - MRI
 - CSF
 - Treatment response
 - Anti-GM1 antibodies

CSF: Cerebrospinal fluid, EFNS: European Federation of Neurological Societies, GM1: ganglioside GM1, MRI: Magnetic Resonance Imaging, PNS: Peripheral Nerve Society

1. van Schaik IN *et al.* Chapter 21: Multifocal motor neuropathy. In: Gilhus, NE *et al.* (Ed). European Handbook of Neurological Management; Volume 1, 2nd Edition. 2011.

Diagnostic guidelines for MMN continued¹

Clinical criteria	Features
Core criteria (both must be present)	<ol style="list-style-type: none">1. Slowly or stepwise progressive, focal, asymmetric limb weakness for more than one nerve2. No objective sensory abnormalities except for minor vibration sense abnormalities in the lower limbs
Supportive clinical criteria	<ol style="list-style-type: none">1. Predominant upper limb involvement2. Decreased or absent tendon reflexes in the affected limb3. Absence of cranial nerve involvement4. Cramps and fasciculations in the affected limb5. Response in terms of disability or muscle strength to immunomodulatory treatment
Exclusion criteria	<ol style="list-style-type: none">1. Upper motor neuron signs2. Marked bulbar involvement3. Sensory impairment more marked than minor vibration loss in the lower limbs4. Diffuse symmetric weakness during the initial weeks

Diagnostic considerations

- MMN must be distinguished from other degenerative motor neuron diseases and CIDP due to differences in prognosis and therapy¹
 - Certain therapies may exacerbate weakness in MMN patients
- Increased levels of IgM antibodies to GM1 are typically used as biomarkers for MMN¹
 - As anti-GM1 IgM is found in 30–80% of patients, there may be antibodies of other specificities that perform a similar function
 - Sensitivity of current assays may affect antibody detection
- Nerve ultrasound can be considered as a complementary tool for the diagnosis of MMN with atypical characteristics²

CIDP: chronic inflammatory demyelinating polyneuropathy, IgM: immunoglobulin M

1. Nobile-Orazio E *et al.* Muscle Nerve. 2005;31(6):663–680.

2. Pitarokoili K *et al.* Muscle Nerve. 2015;52(2):294–299.

|||| Treatment guidelines for MMN¹

- Options are limited to IVIG as MMN patients do not usually respond to plasma exchange or corticosteroids
 - Patients may worsen if they receive these treatments
- Recommended treatment:
 - Induction: 2 g/kg bw IVIG given over 2–5 days
 - If the initial dose is effective, consider repeat dosing in selected patients
 - Maintenance: 1 g/kg bw every 2–4 weeks or 2 g/kg bw every 1–2 months
- During long-term IVIG treatment, effectiveness declines as muscle strength decreases, even when dosage is increased due to ongoing axonal degeneration

bw: bodyweight

1. van Schaik IN *et al.* Chapter 21: Multifocal motor neuropathy. In: Gilhus, NE *et al.* (Ed). European Handbook of Neurological Management; Volume 1, 2nd Edition. 2011.

|||| Treatment options

- IVIG
 - Randomized controlled trials have shown a positive effect;¹ however, a maintenance dose is required every 2–4 weeks or every 1–2 months, depending on the dose²
 - IVIG limits disease progression but does not prevent it³
 - In 2012, a 10% IVIG was approved by FDA for the treatment of MMN⁴
 - Approved for use in Europe in 2011
- Cyclophosphamide: reported to be effective in several case studies³
 - Potential toxicity requires a careful risk:benefit analysis in each patient

FDA: Food and Drug Administration

1. van Schaik IN *et al.* Cochrane Database Syst Rev. 2005;18(2):CD004429.
2. van Schaik IN *et al.* Chapter 21: Multifocal motor neuropathy. In: Gilhus, NE *et al.* (Ed). European Handbook of Neurological Management; Volume 1, 2nd Edition. 2011.
3. Vlam L *et al.* Nat Rev Neurol. 2012;8(1):48–58.
4. Baxter Press Release. Available at: http://www.baxter.com/news-media/newsroom/press-releases/2012/06_25_12_gammagard_mmn.page. Accessed Mar 2016.

Evidence for effect of treatment

- In 2012 the FDA approved a 10% IVIG treatment for MMN¹
 - Approval was based on the results of a randomized controlled trial in 44 MMN patients:²

Primary endpoint	Results
Grip strength in the more affected hand	Mean maximal grip strength of the more affected hand declined by 31.38% with placebo and increased 3.75% with IVIG (p=0.005)
Upper limb sub-section of the Guy's Neurological Disability Scale	Fewer patients experienced deterioration in the drug-treated group compared to placebo; 11.9% vs. 35.7%, respectively (p=0.021)

1. Baxter Press Release. Available at: http://www.baxter.com/news-media/newsroom/press-releases/2012/06_25_12_gammagard_mmn.page. Accessed Mar 2016.

2. Hahn AF *et al.* J Periph Nerv Syst. 2013;18(4);321–330.

Evidence for effect of treatment continued

- Other randomized controlled trials have also shown IVIG to be an effective treatment in MMN patients

Study	Conclusion
Azulay JP <i>et al.</i> Neurology 1994;44:429–432	Compared to placebo, IVIG induced a significant increase in muscle strength in patients with CB
Van den Berg LH <i>et al.</i> J Neurol Neurosurg Psychiatry 1995;59:248–252	IVIG can lead to improvement in muscle strength of MMN patients
Federico P <i>et al.</i> Neurology 2000;55:1256–1262	IVIG improved CB as well as subjective and objective clinical measures of function (grip strength and NDS)
Léger JM <i>et al.</i> Brain 2001;124:145–153	IVIG is a promising therapeutic option for MMN (based upon MRC score in 28 muscles and self-evaluation scale)

CB: conduction block, MRC: Medical Research Council, NDS: neurological disability score

SCIG in MMN

- Studies investigating the use of SCIG for the treatment of MMN have shown it comparable to IVIG*

Study	Results/Conclusion
Misbah SA <i>et al.</i> J Peripher Nerv Syst 2011;16:92–97	MMN patients with stable clinical course on regular IVIG can switch to SCIG at the same monthly dose without deterioration and with a sustained overall improvement in HRQL
Harbo T <i>et al.</i> Neurology 2010;75:1377–1380	Patients were able to maintain function over 2 years and showed no change in impairment or disability scores
Harbo T <i>et al.</i> Eur J Neurol 2009;16:631–638	SCIG and IVIG were equally effective. Mean change in muscle strength: Post-SCIG: 3.6%; Post-IVIG: 4.3%
Eftimov F <i>et al.</i> J Peripher Nerv Syst 2009;14:93–100	SCIG therapy was feasible, safe and as effective as IVIG (based upon MRC sum score from 10 muscle groups)

HRQL: health-related quality of life, SCIG: subcutaneous immunoglobulin

*SCIG is not currently approved for the treatment of MMN. Please check the label for specific information on approved indications.

Summary

- MMN is a rare disorder characterized by asymmetric, predominantly distal limb weakness without sensory loss
- Diagnosis of MMN is based on clinical and electrodiagnostic criteria, and may be supported by laboratory and ultrasound testing
- IVIG is the first-line treatment for MMN patients
 - Corticosteroids are not recommended
 - SCIG therapy has been reported as a feasible, safe and effective therapy for MMN patients, which could be considered as an alternative option to IVIG*

*SCIG is not currently approved for the treatment of MMN. Please check the label for specific information on approved indications.